

A Comprehensive Approach to the Recognition, Diagnosis, and Severity-Based Treatment of Focal Hyperhidrosis: Recommendations of the Canadian Hyperhidrosis Advisory Committee

NOWELL SOLISH, MD, FRCPC,* VINCE BERTUCCI, MD, FRCPC,* ALAIN DANSEREAU, MD, FRCPC,[†] H. CHIH-HO HONG, MD, FRCPC,[‡] CHARLES LYNDE, MD, FRCPC,[§] MARK LUPIN, MD, FRCPC,[‡] KEVIN C. SMITH, MD, FRCPC, FACP,^{||} AND GREG STORWICK, MD, FRCPC[¶]

BACKGROUND Hyperhidrosis can have profound effects on a patient's quality of life. Current treatment guidelines ignore disease severity.

OBJECTIVE The objective was to establish clinical guidelines for the recognition, diagnosis, and treatment of primary focal hyperhidrosis.

METHODS AND MATERIALS A working group of eight nationally recognized experts was convened to develop the consensus statement using an evidence-based approach.

RECOMMENDATIONS An algorithm was designed to consider both disease severity and location. The Hyperhidrosis Disease Severity Scale (HDSS) provides a qualitative measure that allows tailoring of treatment. Mild axillary, palmar, and plantar hyperhidrosis (HDSS score of 2) should initially be treated with topical aluminum chloride (AC). If the patient fails to respond to AC therapy, botulinum toxin A (BTX-A; axillae, palms, soles) and iontophoresis (palms, soles) should be the second-line therapy. In severe cases of axillary, palmar, and plantar hyperhidrosis (HDSS score of 3 or 4), both BTX-A and topical AC are first-line therapy. Iontophoresis is also first-line therapy for palmar and plantar hyperhidrosis. Craniofacial hyperhidrosis should be treated with oral medications, BTX-A, or topical AC as first-line therapy. Local surgery (axillary) and endoscopic thoracic sympathectomy (palms and soles) should only be considered after failure of all other treatment options.

CONCLUSIONS These guidelines offer a rapid method to assess disease severity and to treat primary focal hyperhidrosis according to severity.

All authors received honoraria from Allergan Inc. for participation and/or travel expenses for this study.

Hyperhidrosis, a disorder of excessive sweat, may be focal, involving specific areas of the body, or generalized, involving the entire body. Focal hyperhidrosis most commonly affects the axillae, hands, feet, and face.

The pathophysiology of focal hyperhidrosis is poorly understood. Eccrine glands are distributed around the body with high concentrations in areas such as the palms, soles, and forehead. These glands are innervated by the cholinergic fibers of the sympathetic

*Division of Dermatology, New Women's College Hospital, Toronto, Ontario; [†]Private Practice, Repentigny, Québec; [‡]Department of Dermatology, University of British Columbia, Vancouver, British Columbia; [§]Division of Dermatology, Toronto Western Hospital, Toronto, Ontario; ^{||}Private practice, Niagara Falls, Ontario; [¶]Faculty of Medicine, University of Calgary, Calgary, Alberta, Canada

Disclaimer: Adherence to the recommendations in this article will not ensure successful treatment in every situation. Furthermore, these recommendations should not be deemed inclusive of all proper methods of care or exclusive of other methods of care reasonably directed to obtaining the same results. Final judgment of any specific therapy should be made by the physician and the patient considering all the circumstances presented by the individual patient. All doses and recommendations pertaining to botulinum toxin A (BTX-A) apply specifically to BOTOX (Allergan Inc., Irvine, CA) unless otherwise noted.

© 2007 Crown copyright • Journal compilation © 2007 by the American Society for Dermatologic Surgery, Inc. • Published by Blackwell Publishing • ISSN: 1076-0512 • Dermatol Surg 2007;33:908–923 • DOI: 10.1111/j.1524-4725.2007.33192.x

nervous system. Patients with hyperhidrosis do not demonstrate any histopathologic changes in the sweat glands or changes in their numbers. A complex dysfunction in the sympathetic system likely contributes to the cause. Up to two-thirds of patients report a positive family history, suggesting that a genetic predisposition may exist. Generalized hyperhidrosis may be physiologic or due to autonomic dysfunction secondary to neurologic, endocrinologic, metabolic, and other such disorders, as well as febrile illness, malignancy, and drugs.

Hyperhidrosis may have significant effects on patients' lives including social embarrassment; interference with intimacy, activities of daily living, and certain kinds of employment; and physical discomfort and a negative impact on health-related quality of life (QOL).^{1,2} The effects of hyperhidrosis on QOL have been investigated using numerous tools.²⁻⁵ Clinical experience and results using these tools have shown the deep impact that hyperhidrosis has on affected individuals.

Early identification and proper management of patients with hyperhidrosis are crucial to lessen the emotional, psychosocial, and physical impact of their condition. Clinicians have a number of available treatments for hyperhidrosis. Two guidelines for the recommended treatment of primary focal hyperhidrosis have been published.^{6,7} Since the 2004 publication of the guidelines, new clinical studies that involve an assessment of disease severity have been completed. Proper management of patients with hyperhidrosis, taking into account the severity of disease, is crucial to lessen the burden of their condition.

The purpose of this working group was to review the clinical literature and develop practical guidelines for the treatment of primary focal hyperhidrosis for multiple anatomic regions based on clinical severity.

Methods

A working group of eight nationally recognized experts was convened to review the clinical evidence

and develop the consensus statement. Each advisor had treated between 50 and 200 patients with hyperhidrosis in 2005 (median, 100–149 patients; unpublished results from national survey of top hyperhidrosis-treating physicians in Canada).

The advisors employed an evidence-based approach, performing a comprehensive literature search of English-language articles published from 1967 to 2006 on the diagnosis, recognition, or treatment of hyperhidrosis. Selected publications included randomized trials, controlled or noncontrolled studies, meta-analyses, and single- or multicenter case series. Reviews and unpublished trials were excluded. Literature databases included MEDLINE, PubMed, and EMBASE. The search terms included *hyperhidrosis*, *quality of life*, and *randomized controlled trials*. The level of evidence was assessed for each publication using a scale (I–III) for the quality of evidence (Table 1). Level of evidence (I, II-1, II-2, II-3, III) is indicated after each recommendation. Citations in support of individual recommendations are identified in the guideline text. Following review of the evidence by the advisors, recommendations were drafted, discussed, and voted on by all members.

TABLE 1. Level of Evidence (from Canadian Task Force on Preventive Health Care)

Level	Evidence
I	Evidence obtained from at least one properly designed randomized controlled trial, systematic review or meta-analysis.
II-1	Evidence obtained from well-designed controlled trials without randomization.
II-2	Evidence obtained from well-designed cohort or case-control analytic studies, preferably from more than one center or research group.
II-3	Evidence obtained from multiple time series with or without the intervention; dramatic results in uncontrolled trials might also be regarded as this type of evidence.
III	Opinions of respected authorities, based on clinical experience, descriptive studies, or reports of expert committees.

Recommendations

Assessment

The first step in evaluation of a patient's excessive sweating is to take a complete history and perform a physical examination. Additional laboratory testing is not required if the presentation is characteristic of primary focal hyperhidrosis.⁶ If warranted, however, a directed work-up including appropriate laboratory and radiologic investigations should be completed to rule out other potential causes of hyperhidrosis. Then, if appropriate, a diagnosis of primary focal hyperhidrosis can be made, or other disease states responsible for the hyperhidrosis can be investigated and treated.

The next step in assessing a patient is to establish the severity of hyperhidrosis. Tests such as gravimetry and evaporimetry are used predominantly in research settings to measure the quantity of sweat being produced. There are significant limitations, however, with the use of gravimetry in a clinical setting. The burdensome nature of the test and significant inter- and inpatient variability are among limitations reported.^{6,8} Minor's starch-iodine test is used to assess the size of the surface area involved and is used primarily for assessing the area to treat as it does not give any indication on severity. This test is recommended to delineate the area of treatment and should be performed on every patient unless previous documentation of the area involved has been recorded (i.e., from previous treatment).

The Illness Intrusive Rating Scale (IIRS) measures the extent to which disease, its treatment, or both interfere with activities across 13 life domains considered important to QOL.⁹ A tool specifically designed for hyperhidrosis is the Hyperhidrosis Impact Questionnaire (HHIQ).¹⁰ This questionnaire has items for baseline evaluation and 10 items for use in follow-up treatment. This is a useful tool in a research setting, but not in a practical clinical setting.

The Hyperhidrosis Disease Severity Scale (HDSS) was chosen to measure disease severity in the pro-

Hyperhidrosis Disease Severity Scale

☐ My (underarm) sweating is never noticeable and never interferes with my daily activities Score 1

☐ My (underarm) sweating is tolerable but sometimes interferes with my daily activities Score 2

☐ My (underarm) sweating is barely tolerable and frequently interferes with my daily activities Score 3

☐ My (underarm) sweating is intolerable and always interferes with my daily activities Score 4

Figure 1. Hyperhidrosis Disease Severity Scale.

posed treatment algorithms. It is a disease-specific scale for hyperhidrosis that provides a qualitative measure of the severity of the patient's condition based on how it affects daily activities.¹ The patients select the statement that best reflects their experience with sweating in the specified area. A score of 3 or 4 indicates severe hyperhidrosis, whereas a score of 1 or 2 indicates mild or moderate primary hyperhidrosis (Figure 1).¹¹ This quick diagnostic tool allows the clinician to identify the level of interference with daily activities. It is a single-item instrument that can be rapidly administered in written or interview format, is easily understood, and requires no aids for completion. The validity and reliability of the HDSS were analyzed using three studies and were found to have strong to moderate correlations with the HHQ, Dermatology Life Quality Index [DLQI; 10 items that form six domains, total score of 0 (best) to 30 (worst)], and gravimetric sweat production. A 1-point improvement in HDSS score was associated with a 50% reduction in sweat production and a 2-point improvement with an 80% reduction.^{12–15}

Treatment

There are a wide array of modalities available to treat hyperhidrosis. These include nonsurgical (i.e., topical, systemic) and surgical treatments that vary in their therapeutic efficacy, side effects, cost, and

duration of effect.¹ In all patients who present with hyperhidrosis, it is crucial that the disease severity be measured using the HDSS to determine proper course of treatment and to monitor the results of treatment.

What is the definition of treatment success and treatment failure in patients with hyperhidrosis? Using the HDSS, a treatment success is identified as an improvement from a score of 4 or 3 to a 2 or 1 or from a score of 2 to 1. Treatment failure can be defined as no change in HDSS score after 1 month of therapy or lack of tolerability for the treatment. With botulinum toxin A (BTX-A) injections, it is important to evaluate the treatment area: apparent failure may be due to a small area being missed. In this case, repeat treatment of the symptomatic area with a second round of BTX-A injections (at the same or higher dose) should be done before considering the treatment unsuccessful.

Treatment of Axillary Hyperhidrosis

Recommendations (Figure 2)

HDSS Score of 2

1. For mild or moderate axillary hyperhidrosis, topical aluminum chloride (AC) hexahydrate is the first choice of therapy.^{16,17} An initial concentration of 10% to 12% AC may be tried to minimize irritation. Euhidrosis may not be achieved until a 35% solution is used; however, many patients experience unacceptable skin irritation at this strength (I, II-1, II-2). It may be more effective to apply AC at bedtime than in the morning, and if well tolerated AC may be applied twice daily.

2. If a patient fails to respond to topical therapy after 1 month, intradermal injection of BTX-A may be administered. Recommended dose is 1 U/cm² (3–4 U every 1.5–2 cm)¹⁸ to a total of 50 to 100 U/axilla depending on patient response and surface

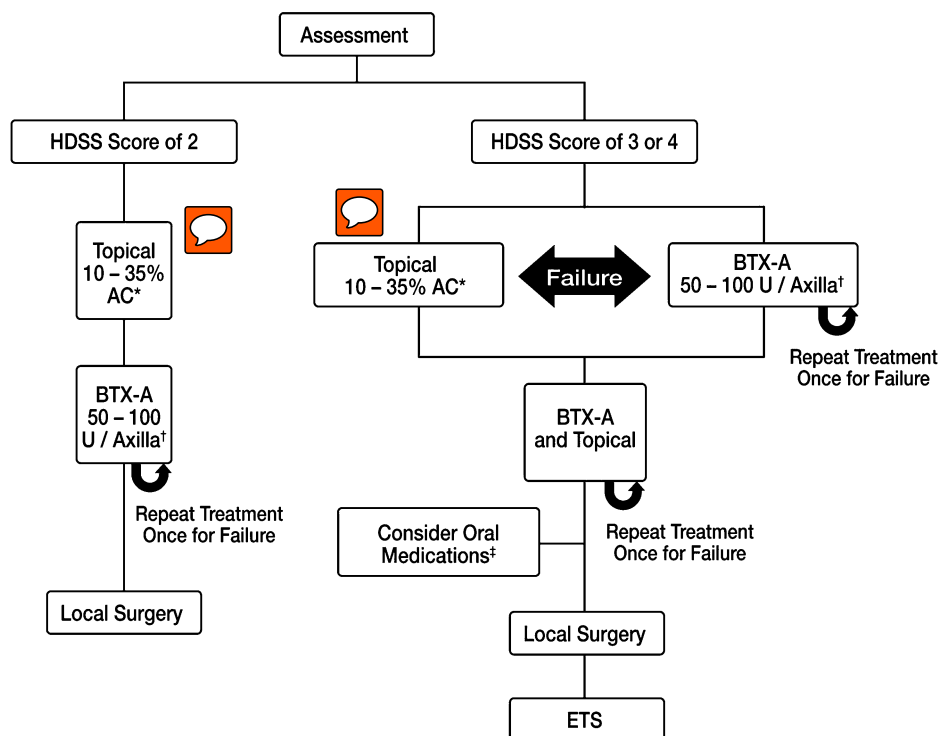


Figure 2. Treatment algorithm for axillary hyperhidrosis. *Apply to dry axilla at bedtime; wash off in 6 to 8 hours. Use three to seven times per week until euhidrotic. Maintenance treatment every 1 to 3 weeks. †Recommended dose is 1 U/cm². ‡Glycopyrrolate (1–2 mg) can be taken three times a day. HDSS, Hyperhidrosis Disease Severity Scale; AC, aluminum chloride; BTX-A, botulinum toxin A; ETS, endoscopic thoracic sympathectomy.

area of involvement (I). Larger surface areas may require a higher dose. Treatment is repeated on average every 4 to 6 months when the patient has a change in HDSS score that warrants treatment.

3. Reduction of sweat glands, done on an outpatient basis with local anesthesia, is the next step should the patient not respond to two treatments with BTX-A (II-1, II-3).

HDSS Score of 3 or 4

1. For severe axillary hyperhidrosis, AC or BTX-A is first-line therapy as outlined in the recommendations for an HDSS score of 2 (above).
2. If a patient fails to respond to topical or BTX-A therapy, consider using both in combination (III).
3. If a patient fails to respond to topical or BTX-A therapy, consider the use of oral medications alone or as an adjuvant therapy (III).
 - a. Glycopyrrolate (1–2 mg) can be taken up to three times/day. (Other anticholinergics are also sometimes used.)
4. Reduction of sweat glands, done on an outpatient basis with local anesthesia, is the next step should the patient not respond to treatment (II-1, II-3).
5. Endoscopic thoracic sympathectomy (ETS) should be the last resort in patients not responding to therapy. Patients must be well informed and willing to accept both the surgical risks and the significant risk of compensatory sweating (II-2).

Discussion

The safety and efficacy of topical AC in the treatment of axillary hyperhidrosis have been shown in two small controlled studies and four open-label observational studies.^{19–24} Sample sizes ranged from 23 to 139 patients, and reduction in sweat was measured using gravimetric measurements or patient-reported outcomes. Topical AC was generally well tolerated, with skin irritation the most common

adverse event reported. Irritation resulted in a decrease in concentration or frequency of application and led to discontinuation in 2% to 21% of patients.

BTX-A is the best-studied treatment for focal hyperhidrosis. It is injected intradermally to treat hyperhidrosis and inhibits the release of acetylcholine at the neuromuscular junction and from the sympathetic nerves that innervate eccrine sweat glands. More than 20 prospective, observational, or placebo-controlled studies have assessed the efficacy and safety of BTX-A in the treatment of axillary hyperhidrosis.^{25–41} All studies showed a significant treatment response by quantitative measures of sweat production or patient-reported outcome measures.

In the largest, randomized, double-blind, placebo-controlled study, patients were treated with 50 U of BTX-A, 75 U of BTX-A, or placebo in each axilla and were followed for 52 weeks. Inclusion criteria included an HDSS score of 3 or 4 and the production of at least 50 mg of sweat in each axilla at rest over 5 minutes. Patients were evaluated every 4 months and reinjected when they reported a reincrease in HDSS score to 3 or 4 and produced 50 mg sweat in each axilla by gravimetric measurement, but no sooner than 8 weeks after the initial injection. Study responders were defined as patients who showed at least a two-grade improvement from baseline value on the HDSS 4 weeks after both of the first two treatment sessions or had a sustained response after their first treatment session and did not receive retreatment during the study. Sweat responders were defined as having at least a 50% reduction in axillary sweat production at Week 4. At 4 weeks, study response rate and sweat response rate were higher in the BTX-A groups (50 U/75 U) compared to the placebo group (55/49 vs. 6% and 81/86 vs. 41%, respectively; $p < .001$).¹⁸

In another randomized, double-blind, placebo-controlled study, patients were treated with 50 U of BTX-A per axilla or placebo and were followed for 16 weeks after treatment. Treatment response was defined as a greater than 50% reduction in

gravimetric sweat rate (mg/5 min). At 4 weeks, response rate was higher in the BTX-A group compared to the placebo-treated patients (94% vs. 36%; $p < .001$), and there was significantly higher patient satisfaction using a global assessment of treatment satisfaction score, where 4 is 100% improvement of signs and symptoms (3.3 vs. 0.8; $p < .001$).⁴²

Routine photography of the starch-iodine test areas can assist in the follow-up evaluation of patients. In cases where the patient claims that there was poor efficacy and/or short duration of effect, often comparison of photos of pretreatment starch-iodine test results with a repeat starch-iodine test will provide objective evidence of a marked reduction in the area of hyperhidrosis (K. Smith, MD, unpublished observations, April 2006).

Local sweat-gland excision by subcutaneous curettage or tumescent liposuction, done on an outpatient basis with local anesthesia, should be the next step if the patient does not respond to BTX-A.^{43–45} Direct excision can create significant scarring and is associated with prolonged recovery time. The efficacy of surgical treatments was measured in a study by Proebstle and coworkers⁴⁶ in which 42 patients received subcorial curettage using a sharp spoon under tumescent local anesthesia. Sweat rates were determined gravimetrically, and curettage was found to be effective in the treatment of axillary hyperhidrosis in patients with baseline sweat rates greater than 25 mg/min.

ETS is generally not recommended and should be considered the last treatment option only in patients with severe axillary hyperhidrosis. Two studies examined the long-term outcomes after ETS and found that permanent side effects impaired patient satisfaction; compensatory sweating was seen in 67% of patients, and individuals treated for axillary hyperhidrosis without palmar involvement were significantly less satisfied with ETS treatment (33% vs. 67%).^{47,48}

Compelling evidence is lacking for the safety and efficacy of systemic anticholinergic agents and ion-

tophoresis for the treatment of axillary hyperhidrosis. Only in severe cases of hyperhidrosis should anticholinergics be considered, because the dosing necessary to alleviate symptoms of hyperhidrosis results in complications and adverse events such as blurred vision, dry mouth and eyes, palpitations, and urinary retention. Iontophoresis is difficult to administer to the axillae and frequently results in irritation.^{49–51}

Treatment of Palmar HH

Recommendations (Figure 3)

HDSS Score of 2

1. **For mild or moderate palmar hyperhidrosis, topical AC hexahydrate in absolute ethanol or in a salicylic acid gel is the therapy of first choice. An initial concentration of 10% to 12% AC may be tried to minimize irritation; however, a higher concentration may be necessary to achieve euhidrosis.** Some patients may tolerate a concentration of up to 50% AC but the risk of skin irritation is higher at this concentration (II-2).
2. If a patient fails to respond to topical therapy, intradermal injection of BTX-A may be administered or iontophoresis therapy initiated.
 - a. An initial dose of 100 U of BTX-A per palm has been shown to be effective but may need to be increased to 150 U per palm depending on patient response (I). Recommended dose is 1.5 to 2 U/cm² with a mean dose of 100 U per palm. In certain instances a smaller dose of BTX-A may be needed due to small surface area involvement. Proper anesthesia use is vital to the success of treatment.
 - b. Tap-water iontophoresis requires proper patient education on technique for optimal effect (I).
 - i. Patients undergo 3 to 4 treatments per week for 20 to 30 minutes using a device that provides a direct current of 15 to 20 mA. Because the anode may be more effective, the current



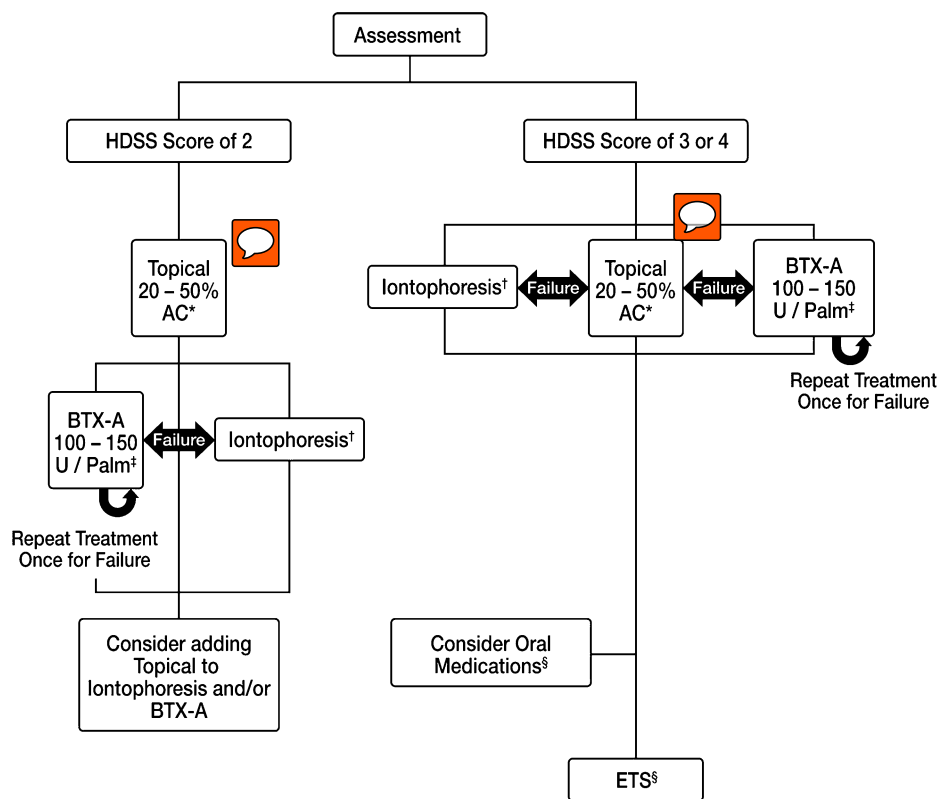


Figure 3. Treatment algorithm for palmar hyperhidrosis. *Apply to dry palm at bedtime; wash off in 6 to 8 hours. Use three to seven times per week until euhidrotic. Maintenance treatment every 1 to 3 weeks. †Direct current at 10 to 20 mA for 20 to 30 minutes. Switch current direction midway through treatment. Use every other day until euhidrotic. Maintenance treatment every 1 to 4 weeks. ‡Recommended dose is 1.5 to 2 U/cm². Proper anesthesia use is crucial to treatment success. §Glycopyrrolate (1–2 mg) can be taken three times a day. HDSS, Hyperhidrosis Disease Severity Scale; AC, aluminum chloride; BTX-A, botulinum toxin A; ETS, endoscopic thoracic sympathectomy.

direction is switched halfway through the treatment.

- ii. Once euhidrosis has been achieved (typically following 6–10 treatments), frequency of maintenance treatments is titrated for individual response. Maintenance treatments are typically required at 1- to 4-week intervals.

3. If a patient fails to respond to BTX-A or iontophoresis alone, consider adding topical AC hexahydrate (at a concentration recommended in 1) to therapy (III).

HDSS Score of 3 or 4

1. For severe palmar hyperhidrosis, AC, BTX-A, or iontophoresis are all considered to be first-line

therapy as outlined in the recommendations for an HDSS score of 2.

2. If a patient fails to respond to topical therapy, BTX-A, or iontophoresis, consider the use of oral medications alone or as adjuvant therapy (III).
 - a. Glycopyrrolate (1–2 mg) can be taken up to three times per day.
 - b. Iontophoresis with glycopyrrolate solution has been shown to increase efficacy of iontophoresis but can increase side effects.
3. ETS should be the last resort in patients not responding to therapy. Patients must be well informed and willing to accept both the surgical

risks and the significant risk of compensatory hyperhidrosis (I).

Discussion

The safety and efficacy of topical AC in the treatment of palmar hyperhidrosis have been shown in four small observational studies.^{52–55} Reduction in sweat was measured using evaporimetric measurements, transpiration measurements, or patient-reported outcomes.

Several studies have been performed examining the efficacy and safety of BTX-A in the treatment of palmar hyperhidrosis.^{56–66} Duration of euhidrosis by and large exceeded the length of the study and response rate was consistently above 90%. The most noteworthy adverse event was transient weakness of the intrinsic hand muscles, for which patients should be counseled regarding dangers of poor fine motor control.^{67–72} Proper use of anesthesia is vital to the success of BTX-A in the treatment of palmar hyperhidrosis due to the intense pain associated with multiple injections into the palms. Bier's block, nerve blocks, application of ice or cold air before and after injection, and vibration have all been shown to be successful in reducing pain during treatment.^{73–78} Proper counseling on the potential side effects of anesthesia should inform the patient of possible damage to peripheral nerves and vessels.

Three small controlled studies confirmed the efficacy of tap-water iontophoresis in the treatment of palmar hyperhidrosis.^{79–81} More recently, iontophoresis performed with anticholinergic agents in solution has been shown to potentiate the euhidrotic effect; however, patients frequently report adverse events, including dry mouth, commonly seen with oral anticholinergic therapy.^{82–84}

Compelling evidence is lacking for the safety and efficacy of systemic anticholinergic agents for the treatment of palmar hyperhidrosis. Owing to systemic adverse events seen at concentrations neces-

sary to treat hyperhidrosis, anticholinergics should only be used in severe cases.⁸⁵

More than 40 published reports examine the efficacy and safety of ETS in palmar hyperhidrosis.^{48,86–131} These reports lack consistency in patient selection, surgical technique, and quantitative and qualitative measurement of hyperhidrosis and QOL. Although success rates range from 92% to 100%, there are significant complications associated with sympathectomy. These complications include pneumothorax, gustatory sweating, rhinitis, and Horner's syndrome.^{126,132} ETS has decreased the risk of adverse events. Patients are often satisfied with ETS in palmar hyperhidrosis, yet compensatory sweating may at times be worse than the original condition being treated.

Treatment of Plantar HH

Recommendations (Figure 4)

HDSS Score of 2

1. **For mild or moderate plantar hyperhidrosis, topical AC hexahydrate in absolute ethanol or in a salicylic acid gel is the first choice of therapy. An initial concentration of 20% AC may be tried to minimize irritation; however, a higher concentration may be necessary to achieve euhidrosis.** Some patients may tolerate a concentration of up to 50% AC but the risk of skin irritation is higher at this concentration (II-2).
2. If a patient fails to respond to topical therapy, intradermal injection of BTX-A may be administered or iontophoresis therapy initiated.
 - a. An initial dose of 150 U of BTX-A per sole has been shown to be effective but may need to be increased to 200 U per sole depending on patient response and surface area involvement (I). The recommended dose is 1.5 to 2 U/cm² with a mean dose of 150 U per sole. In certain instances, a smaller dose of BTX-A may be needed due to small surface area involvement.



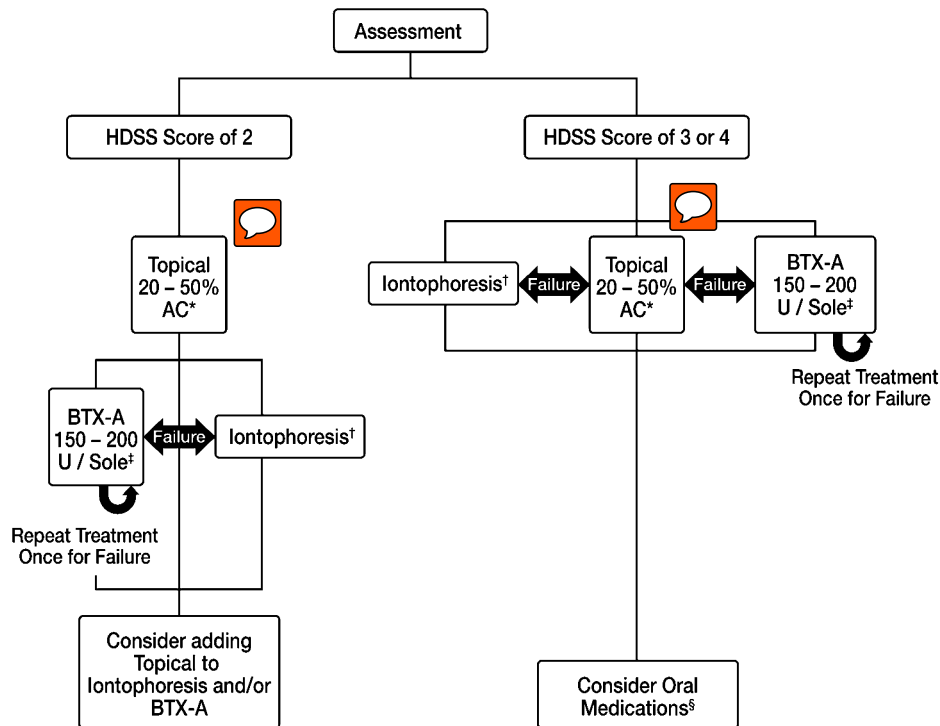


Figure 4. Treatment algorithm for plantar hyperhidrosis. *Apply to dry sole at bedtime; wash off in 6 to 8 hours. Use three to seven times per week until euhidrotic. Maintenance treatment every 1 to 3 weeks. †Direct current at 10 to 20 mA for 20 to 30 minutes. Switch current direction midway through treatment. Use every other day until euhidrotic. Maintenance treatment every 1 to 4 weeks. ‡Recommended dose is 1.5 to 2 U/cm². Proper anesthesia use is crucial to treatment success. §Glycopyrrolate (1–2 mg) can be taken three times a day. HDSS, Hyperhidrosis Disease Severity Scale; AC, aluminum chloride; BTX-A, botulinum toxin A.

Proper anesthesia use is vital to the success of treatment.

- b. Tap-water iontophoresis requires proper patient education on technique for optimal effect (I). The technique is similar to that described for palmar hyperhidrosis.
3. If a patient fails to respond to BTX-A or iontophoresis alone, consider adding topical AC hexahydrate (at a concentration recommended in 1) to therapy (III).
4. For patients suffering from palmoplantar hyperhidrosis, the expert panel consensus with BTX-A therapy is to initially treat only the palms as there is often a reduction in plantar hyperhidrosis following treatment of only the palms (III). It is unknown whether this may also occur using other treatments.

HDSS Score of 3 or 4

1. For severe plantar hyperhidrosis, AC, BTX-A, or iontophoresis are all first-line therapy as outlined in the recommendations for an HDSS score of 2.
2. If a patient fails to respond to topical therapy, BTX-A, or iontophoresis, consider the use of oral medications alone or as adjuvant therapy (III).
 - a. Glycopyrrolate (1–2 mg) can be taken up to three times per day.
 - b. Iontophoresis with glycopyrrolate solution has been shown to increase efficacy of iontophoresis but can increase systemic side effects.
3. For patients suffering from palmoplantar hyperhidrosis, the expert panel consensus with BTX-A therapy is to initially treat only the palms as there is often a reduction in plantar hyperhidrosis

after treatment of only the palms (III). It is unknown whether this may also occur using other treatments.

Discussion

Compared to axillary and palmar hyperhidrosis, fewer publications examine the safety and efficacy of treatments for plantar hyperhidrosis. In two observational studies, patients became euhidrotic after application of 20 or 25% AC in ethanol.^{54,133} AC has also been investigated in a large study of 139 patients in which patients had good or excellent response to 30% to 40% AC in salicylic acid gel.¹³⁴ Tap-water iontophoresis has also been shown to be effective in treating plantar hyperhidrosis.^{135–137}

There are only two published trials on the use of BTX-A for plantar hyperhidrosis. In one study, 10 adult patients were injected with 50 U of BTX-A over 15 to 20 injection sites on the soles. After 5 months, 7 of the 10 patients were symptom-free, and self-reported satisfaction with the treatment outcome was 70%.¹³⁸ In another observational study, 6 soles were injected with 100 U of BTX-A per sole and observed for 10 months to evaluate the efficacy and tolerability of BTX-A for plantar hyperhidrosis.

Quantitatively measured, the mean sweat production was found to be significantly lower following BTX-A treatment ($p < .01$).^{138,139}

Treatment of Craniofacial HH

Recommendations (Figure 5)

HDSS Score of 2

1. For mild or moderate craniofacial hyperhidrosis, AC, BTX-A, or oral medications are all first-line therapy.

- a. An initial concentration of 10% AC may be tried to minimize irritation; however, a higher concentration of up to 20% AC may be necessary to achieve euhidrosis. The risk of skin irritation rises with AC concentration (III).

- b. Intradermal injection of BTX-A may be administered. Doses of up to 100 U may be necessary depending on the area injected (II-2).

- i. Knowledge of underlying facial musculature is imperative.

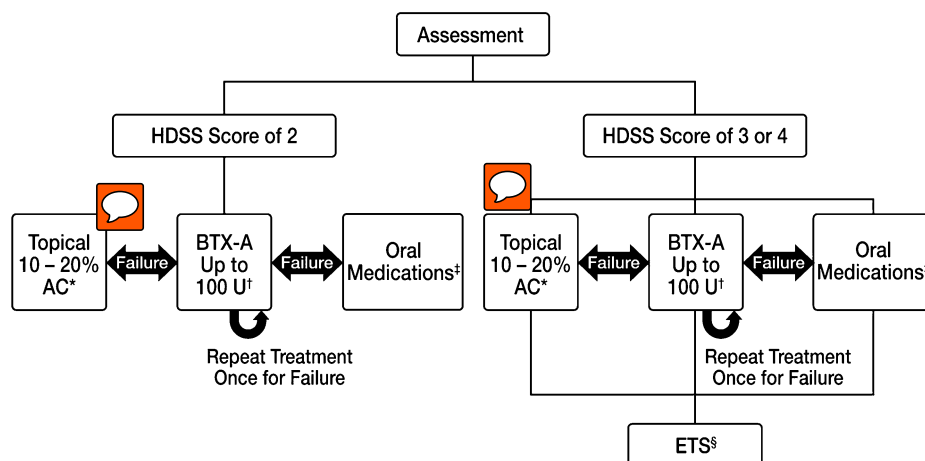


Figure 5. Treatment algorithm for craniofacial hyperhidrosis. *Apply at bedtime; wash off in 6 to 8 hours. Use three times per week until euhidrotic. Maintenance treatment every 1 to 3 weeks. †Knowledge of underlying facial musculature is imperative. Very small areas like the upper lips require only a small amount. BTX-A is the treatment of choice for Frey's syndrome. ‡Glycopyrrolate (1–2 mg) can be taken three times a day. §Only consider for severe hyperhidrosis, especially those associated with facial flushing.

- ii. Very small areas such as the upper lips require only a small amount, starting at 0.5 U/cm².
 - iii. BTX-A is the treatment of choice for Frey's syndrome (gustatory sweating; II-1).
- c. Glycopyrrolate (1–2 mg) can be taken up to three times per day (III).
- i. May be considered for more extensive involvement of face and/or scalp.

HDSS Score of 3 or 4

1. For severe craniofacial hyperhidrosis, first-line therapy is the same as outlined in the recommendations for an HDSS score of 2 (above).
2. ETS should be the last resort in patients not responding to therapy. Patients must be well informed and willing to accept the previously noted risks.
 - a. ETS should be considered only for patients with severe hyperhidrosis especially those associated with facial flushing (III).

Discussion

Craniofacial hyperhidrosis can present as secondary to Frey's syndrome and diabetic neuropathy or as primary craniofacial hyperhidrosis. All manifestations are treated in a similar manner. No published controlled studies look at the efficacy of topical AC in the treatment of craniofacial hyperhidrosis. A small observational study examined nine patients suffering from Frey's syndrome and found that topical application of AC hexahydrate was successful in controlling gustatory sweating using application intervals varying from 1 to 50 days.¹⁴⁰ Topical application of glycopyrrolate has also been studied and found to be effective in patients with Frey's syndrome and diabetic neuropathy.^{141–143} It may have a similar effect on primary craniofacial hyperhidrosis.

BTX-A has been investigated in several studies for the treatment of Frey's syndrome.^{144–153} In one

study, 33 patients were injected with BTX-A (range, 16–80 U; 1 U/cm²) and all relevant clinical symptoms of sweating disappeared within 1 week after a single injection.¹⁵⁴ BTX-A has also been shown to be effective in a small series examining frontal hyperhidrosis in which patients were euhidrotic for over 5 months.¹⁵⁵

The safety and efficacy of ETS for craniofacial hyperhidrosis has not been extensively studied. This treatment should be the last resort for patients with severe hyperhidrosis. Patients should be informed of adverse events, high risk of compensatory hyperhidrosis, and success rate before surgery.^{156–159}

Summary

The HDSS provides a rapid, efficient, and validated method to assess primary focal hyperhidrosis. This qualitative measure allows the clinician to tailor treatment based on the severity of focal hyperhidrosis. The guidelines proposed by the expert panel provide a recommended course of therapy for patients based on the severity of disease.

Mild axillary, palmar, and plantar hyperhidrosis (HDSS score of 2) should initially be treated with topical AC. If the patient fails to respond to AC therapy, BTX-A (axillae, palms, soles) and iontophoresis (palms, soles) should be the second-line therapy. **In severe cases of axillary, palmar, and plantar hyperhidrosis (HDSS score of 3 or 4), both BTX-A and topical AC are first-line therapy.** For palmar and plantar hyperhidrosis, iontophoresis is also first-line therapy. Local surgery and ETS should only be considered in severe cases of hyperhidrosis in which the patient fails to respond to all other treatment options. **Craniofacial hyperhidrosis should be treated with oral medications, BTX-A, or topical AC as first-line therapy regardless of disease severity.** In severe cases of craniofacial hyperhidrosis (HDSS score of 3 or 4), especially those associated with facial flushing, ETS may be considered as a last resort for patients not responding to other therapies.



References

- Haider A, Solish N. Focal hyperhidrosis: diagnosis and management. *CMAJ* 2005;172:69–75.
- Weber A, Heger S, Sinkgraven R, et al. Psychosocial aspects of patients with focal hyperhidrosis: marked reduction of social phobia, anxiety and depression and increased quality of life after treatment with botulinum toxin A. *Br J Dermatol* 2005;152:342–5.
- Kuo CH, Yen M, Lin PC. Developing an instrument to measure quality of life of patients with hyperhidrosis. *J Nurs Res* 2004;12:21–30.
- de C Jr, Kauffman P, Werebe EC, et al. Quality of life, before and after thoracic sympathectomy: report on 378 operated patients. *Ann Thorac Surg* 2003;76:886–91.
- Amir M, Arish A, Weinstein Y, et al. Impairment in quality of life among patients seeking surgery for hyperhidrosis (excessive sweating): preliminary results. *Isr J Psychiatry Relat Sci* 2000;37:25–31.
- Hornberger J, Grimes K, Naumann M, et al. Recognition, diagnosis, and treatment of primary focal hyperhidrosis. *J Am Acad Dermatol* 2004;51:274–86.
- Lowe N, Campanati A, Bodokh I, et al. The place of botulinum toxin type A in the treatment of focal hyperhidrosis. *Br J Dermatol* 2004;151:1115–22.
- Swartling C, Naver H, Lindberg M. Botulinum A toxin improves life quality in severe primary focal hyperhidrosis. *Eur J Neurol* 2001;8:247–52.
- Cina CS, Clase CM. The Illness Intrusiveness Rating Scale: a measure of severity in individuals with hyperhidrosis. *Qual Life Res* 1999;8:693–8.
- Naumann MK, Hamm H, Lowe NJ. Effect of botulinum toxin type A on quality of life measures in patients with excessive axillary sweating: a randomized controlled trial. *Br J Dermatol* 2002;147:1218–26.
- Solish N, Benohanian A, Kowalski JW. Prospective open-label study of botulinum toxin type A in patients with axillary hyperhidrosis: effects on functional impairment and quality of life. *Dermatol Surg* 2005;31:405–13.
- Solish N, Benohanian A, Kowalski JW. Prospective open-label study of botulinum toxin type A in patients with axillary hyperhidrosis: effects on functional impairment and quality of life. *Dermatol Surg* 2005;31:405–13.
- Strutton DR, Kowalski JW, Glaser DA, et al. US prevalence of hyperhidrosis and impact on individuals with axillary hyperhidrosis: results from a national survey. *J Am Acad Dermatol* 2004;51:241–8.
- Lowe NJ, Glaser DA. Botulinum toxin type A in primary axillary hyperhidrosis: a 52-week multi-center double-blind randomized placebo-controlled trial. Poster presented at: 62nd Annual Meeting of the American Academy of Dermatology; February 6–10, 2004; Washington, DC. Poster P195. *J Am Acad Dermatol* 2004;50:50.6–2–2004.
- Kowalski JW, Eadie N, Lai PY, et al. Validity and reliability of the Hyperhidrosis Disease Severity Scale (HDSS). Poster Presented at: 62nd Annual Meeting of the American Academy of Dermatology; February 6–10, 2004; Washington, DC. Poster P198. *J Am Acad Dermatol* 2004;50:51.2006.
- Eisenach JH, Atkinson JL, Fealey RD. Hyperhidrosis: evolving therapies for a well-established phenomenon. *Mayo Clin Proc* 2005;80:657–66.
- Togel B, Greve B, Raulin C. Current therapeutic strategies for hyperhidrosis: a review. *Eur J Dermatol* 2002;12:219–23.
- BOTOX product monograph. Irvine (CA): Allergan Inc; 2004.
- Rayner CR, Ritchie ID, Stark GP. Axillary hyperhidrosis, 20% aluminum chloride hexahydrate, and surgery. *Br Med* 1980;280:1168.
- Scholes KT, Crow KD, Ellis JP, et al. Axillary hyperhidrosis treated with alcoholic solution of aluminium chloride hexahydrate. *Br Med* 1978;2:84–5.
- Benohanian A, Dansereau A, Bolduc C, et al. Localized hyperhidrosis treated with aluminum chloride in a salicylic acid gel base. *Int J Dermatol* 1998;37:701–3.
- Glent-Madsen L, Dahl JC. Axillary hyperhidrosis: local treatment with aluminium-chloride hexahydrate 25% in absolute ethanol with and without supplementary treatment with triethanolamine. *Acta Derm Venereol* 1988;68:87–9.
- Ellis H, Scurr JH. Axillary hyperhidrosis—topical treatment with aluminium chloride hexahydrate. *Postgrad Med* 1979;55:868–9.
- Holzle E, Braun-Falco O. Structural changes in axillary eccrine glands following long-term treatment with aluminium chloride hexahydrate solution. *Br J Dermatol* 1984;110:399–403.
- Naumann M, Lowe NJ. Botulinum toxin type A in treatment of bilateral primary axillary hyperhidrosis: randomised, parallel group, double blind, placebo controlled trial. *BMJ* 2001;323:596–9.
- Heckmann M, Ceballos-Baumann AO, Plewig G. Botulinum toxin A for axillary hyperhidrosis (excessive sweating). *N Engl J Med* 2001;344:488–93.
- Odderson IR. Long-term quantitative benefits of botulinum toxin type A in the treatment of axillary hyperhidrosis. *Dermatol Surg* 2002;28:480–3.
- Naver H, Swartling C, Aquilonius SM. Palmar and axillary hyperhidrosis treated with botulinum toxin: one-year clinical follow-up. *Eur J Neurol* 2000;7:55–62.
- Schnider P, Binder M, Kittler H, et al. A randomized, double-blind, placebo-controlled trial of botulinum A toxin for severe axillary hyperhidrosis. *Br J Dermatol* 1999;140:677–80.
- Tan SR, Solish N. Long-term efficacy and quality of life in the treatment of focal hyperhidrosis with botulinum toxin A. *Dermatol Surg* 2002;28:495–9.
- Wollina U, Karamfilov T, Konrad H. High-dose botulinum toxin type A therapy for axillary hyperhidrosis markedly prolongs the relapse-free interval. *J Am Acad Dermatol* 2002;46:536–40.
- Salmanpoor R, Rahmanian MJ. Treatment of axillary hyperhidrosis with botulinum-A toxin. *Int J Dermatol* 2002;41:428–30.
- Whatling PJ, Collin J. Botulinum toxin injection is an effective treatment for axillary hyperhidrosis. *Br J Surg* 2001;88:814–5.

34. Heckmann M, Breit S, Ceballos-Baumann A, et al. Side-controlled intradermal injection of botulinum toxin A in recalcitrant axillary hyperhidrosis. *J Am Acad Dermatol* 1999;41:987-90.
35. Bushara KO, Park DM, Jones JC, et al. Botulinum toxin—a possible new treatment for axillary hyperhidrosis. *Clin Exp Dermatol* 1996;21:276-8.
36. Glogau RG. Botulinum A neurotoxin for axillary hyperhidrosis: no sweat Botox. *Dermatol Surg* 1998;24:817-9.
37. Heckmann M, Plewig G. Low-dose efficacy of botulinum toxin A for axillary hyperhidrosis: a randomized, side-by-side, open-label study. *Arch Dermatol* 2005;141:1255-9.
38. Solish N, Benohanian A, Kowalski JW. Prospective open-label study of botulinum toxin type A in patients with axillary hyperhidrosis. effects on functional impairment and quality of life. *Dermatol Surg* 2005;31:405-13.
39. Galadari I, Alkaabi J. Botulinum toxin in the treatment of axillary hyperhidrosis. *Skinmed* 2003;2:209-11.
40. Naumann M, Lowe NJ, Kumar CR, et al. Botulinum toxin type a is a safe and effective treatment for axillary hyperhidrosis over 16 months: a prospective study. *Arch Dermatol* 2003;139:731-6.
41. Campanati A, Penna L, Guzzo T, et al. Quality-of-life assessment in patients with hyperhidrosis before and after treatment with botulinum toxin: results of an open-label study. *Clin Ther* 2003;25:298-308.
42. Naumann M, Lowe NJ. Botulinum toxin type A in treatment of bilateral primary axillary hyperhidrosis: randomised, parallel group, double blind, placebo controlled trial. *BMJ* 2001;323:596-9.
43. Bieniek A, Bialynicki-Birula R, Baran W, et al. Surgical treatment of axillary hyperhidrosis with liposuction equipment: risks and benefits. *Acta Dermatovenerol Croat* 2005;13:212-8.
44. Lee MR, Ryman WJ. Liposuction for axillary hyperhidrosis. *Australas J Dermatol* 2005;46:76-9.
45. Payne CM, Doe PT. Liposuction for axillary hyperhidrosis. *Clin Exp Dermatol* 1998;23:9-10.
46. Proebstle TM, Schneiders V, Knop J. Gravimetrically controlled efficacy of subcorial curettage: a prospective study for treatment of axillary hyperhidrosis. *Dermatol Surg* 2002;28:1022-6.
47. Herbst F, Plas EG, Fugger R, et al. Endoscopic thoracic sympathectomy for primary hyperhidrosis of the upper limbs: A critical analysis and long-term results of 480 operations. *Ann Surg* 1994;220:86-90.
48. Zacherl J, Huber ER, Imhof M, et al. Long-term results of 630 thoracoscopic sympathectomies for primary hyperhidrosis: the Vienna experience. *Eur J Surg* 1998;Suppl:43-6.
49. Abell E, Morgan K. The treatment of idiopathic hyperhidrosis by glycopyrronium bromide and tap water iontophoresis. *Br J Dermatol* 1974;91:87-91.
50. Grice K. Hyperhidrosis and its treatment by iontophoresis. *Physiotherapy* 1980;66:43-4.
51. Holzle E, Ruzicka T. Treatment of hyperhidrosis by a battery-operated iontophoretic device. *Dermatologica* 1986;172:41-7.
52. Benohanian A, Dansereau A, Bolduc C, et al. Localized hyperhidrosis treated with aluminium chloride in a salicylic acid gel base. *Int J Dermatol* 1998;37:701-3.
53. Goh CL. Aluminum chloride hexahydrate versus palmar hyperhidrosis: evaporimeter assessment. *Int J Dermatol* 1990;29:368-70.
54. Jensen O, Karlsmark T. Palmoplantar hyperhidrosis: treatment with alcohol solution of aluminium chloride hexahydrate: a simple method of transpiration measurement. *Dermatologica* 1980;161:133-5.
55. Innocenzi D, Lupi F, Bruni F, et al. Efficacy of a new aluminium salt thermophobic foam in the treatment of axillary and palmar primary hyperhidrosis: a pilot exploratory trial. *Curr Med Opin* 2005;21:1949-53.
56. Lowe NJ, Yamauchi PS, Lask GP, et al. Efficacy and safety of botulinum toxin type a in the treatment of palmar hyperhidrosis: a double-blind, randomized, placebo-controlled study. *Dermatol Surg* 2002;28:822-7.
57. Sevim S, Dogu O, Kaleagasi H. Botulinum toxin-A therapy for palmar and plantar hyperhidrosis. *Acta Neurol Belg* 2002;102:167-70.
58. Saadia D, Voustianiouk A, Wang AK, et al. Botulinum toxin type A in primary palmar hyperhidrosis: randomized, single-blind, two-dose study. *Neurology* 2001;57:2095-9.
59. Wollina U, Karamfilov T. Botulinum toxin A for palmar hyperhidrosis. *J Eur Acad Dermatol Venereol* 2001;15:555-8.
60. Naver H, Swartling C, Aquilonius SM. Palmar and axillary hyperhidrosis treated with botulinum toxin: one-year clinical follow-up. *Eur J Neurol* 2000;7:55-62.
61. Solomon BA, Hayman R. Botulinum toxin type A therapy for palmar and digital hyperhidrosis. *J Am Acad Dermatol* 2000;42:1026-9.
62. Schnider P, Binder M, Auff E, et al. Double-blind trial of botulinum A toxin for the treatment of focal hyperhidrosis of the palms. *Br J Dermatol* 1997;136:548-52.
63. Krogstad AL, Skymne A, Pegenius G, et al. No compensatory sweating after botulinum toxin treatment of palmar hyperhidrosis. *Br J Dermatol* 2005;152:329-33.
64. Campanati A, Lagalla G, Penna L, et al. Local neural block at the wrist for treatment of palmar hyperhidrosis with botulinum toxin: technical improvements. *J Am Acad Dermatol* 2004;51:345-8.
65. Campanati A, Penna L, Guzzo T, et al. Quality-of-life assessment in patients with hyperhidrosis before and after treatment with botulinum toxin: results of an open-label study. *Clin Ther* 2003;25:298-308.
66. Swartling C, Farnstrand C, Abt G, et al. Side-effects of intradermal injections of botulinum A toxin in the treatment of palmar hyperhidrosis: a neurophysiological study. *Eur J Neurol* 2001;8:451-6.
67. Naver H, Swartling C, Aquilonius SM. Palmar and axillary hyperhidrosis treated with botulinum toxin: one-year clinical follow-up. *Eur J Neurol* 2000;7:55-62.
68. Tan SR, Solish N. Long-term efficacy and quality of life in the treatment of focal hyperhidrosis with botulinum toxin A. *Dermatol Surg* 2002;28:495-9.

69. Saadia D, Voustantioun A, Wang AK, et al. Botulinum toxin type A in primary palmar hyperhidrosis: randomized, single-blind, two-dose study. *Neurology* 2001;57:2095-9.
70. Schnider P, Binder M, Auff E, et al. Double-blind trial of botulinum A toxin for the treatment of focal hyperhidrosis of the palms. *Br J Dermatol* 1997;136:548-52.
71. Solomon BA, Hayman R. Botulinum toxin type A therapy for palmar and digital hyperhidrosis. *J Am Acad Dermatol* 2000;42:1026-9.
72. Swartling C, Farnstrand C, Abt G, et al. Side-effects of intradermal injections of botulinum A toxin in the treatment of palmar hyperhidrosis: a neurophysiological study. *Eur J Neurol* 2001;8:451-6.
73. Smith KC, Comite SL, Balasubramanian S, et al. Vibration anesthesia: a noninvasive method of reducing discomfort prior to dermatologic procedures. *Dermatol Online J* 2004;10:1.
74. Benohanian A. Surgical pearl: use of needle-free anesthesia in the treatment of palmar hyperhidrosis with botulinum A toxin. *J Am Acad Dermatol* 2005;52:1073-4.
75. Campanati A, Lagalla G, Penna L, et al. Local neural block at the wrist for treatment of palmar hyperhidrosis with botulinum toxin: technical improvements. *J Am Acad Dermatol* 2004;51:345-8.
76. Hund M, Rickert S, Kinkelin I, et al. Does wrist nerve block influence the result of botulinum toxin A treatment in palmar hyperhidrosis? *J Am Acad Dermatol* 2004;50:61-2.
77. Hayton MJ, Stanley JK, Lowe NJ. A review of peripheral nerve blockade as local anaesthesia in the treatment of palmar hyperhidrosis. *Br J Dermatol* 2003;149:447-51.
78. Smith KC, Comite SL, Storwick GS. Ice minimizes discomfort associated with injection of botulinum toxin type a for the treatment of palmar and plantar hyperhidrosis. *Dermatol Surg* 2007;33:588-91.
79. Dahl JC, Glent-Madsen L. Treatment of hyperhidrosis manuum by tap water iontophoresis. *Acta Derm Venereol* 1989;69:346-8.
80. Reinauer S, Neusser A, Schauf G, et al. Iontophoresis with alternating current and direct current offset (AC/DC iontophoresis): a new approach for the treatment of hyperhidrosis. *Br J Dermatol* 1993;129:166-9.
81. Stolman LP. Treatment of excess sweating of the palms by iontophoresis. *Arch Dermatol* 1987;123:893-6.
82. Dolianitis C, Scarff CE, Kelly J, et al. Iontophoresis with glycopyrrolate for the treatment of palmoplantar hyperhidrosis. *Australas J Dermatol* 2004;45:208-12.
83. Abell E, Morgan K. The treatment of idiopathic hyperhidrosis by glycopyrronium bromide and tap water iontophoresis. *Br J Dermatol* 1974;91:87-91.
84. Grice K, Sattar H, Baker H. Treatment of idiopathic hyperhidrosis with iontophoresis of tap water and poldine methosulphate. *Br J Dermatol* 1972;86:72-8.
85. Boni R. Generalized hyperhidrosis and its systemic treatment. *Curr Probl Dermatol* 2002;30:44-7.
86. Masters A, Rennie JA. Endoscopic transthoracic sympathectomy for idiopathic upper limb hyperhidrosis. *Clin Auton Res* 1992;215:289-93.
87. Edmondson RA, Banerjee AK, Rennie JA. Endoscopic transthoracic sympathectomy in the treatment of hyperhidrosis. *Ann Surg* 1992;215:289-93.
88. Kao MC. Video endoscopic sympathectomy using a fiberoptic CO₂ laser to treat palmar hyperhidrosis. *Neurosurgery* 1992;30:131-5.
89. Chao C, Tsai CT, Hsiao HC, et al. Transaxillary endoscopic sympathectomy—a report of experience in 150 patients with palmar hyperhidrosis. *Surg Laparosc Endosc* 1993;3:365-9.
90. Chou SH, Lee SH, Kao EL. Thoracic endoscopic T2-T3 sympathectomy in palmar hyperhidrosis. experience of 112 cases. *Surg Today* 1993;23:105-7.
91. Shachor D, Jedeikin R, Olsfanger D, et al. Endoscopic transthoracic sympathectomy in the treatment of primary hyperhidrosis: a review of 290 sympathectomies. *Arch Surg* 1994;129:241-4.
92. Kao MC, Tsai JC, Lai DM, et al. Autonomic activities in hyperhidrosis patients before, during, and after endoscopic laser sympathectomy. *Neurosurgery* 1994;34:262-8.
93. Chen HJ, Cheng MH, Lin TK, et al. Recordings of pre- and postoperative sympathetic skin response in patients with palmar hyperhidrosis. *Stereotact Funct Neurosurg* 1995;64:214-20.
94. Drott C, Claes G. Hyperhidrosis treated by thoracoscopic sympathectomy. *Cardiovasc Surg* 1996;4:788-90.
95. Kao MC, Lin JY, Chen YL, et al. Minimally invasive surgery: video endoscopic thoracic sympathectomy for palmar hyperhidrosis. *Ann Acad Med* 1996;25:673-8.
96. Lin CC, Mo LR. Experience in thoracoscopic sympathectomy for hyperhidrosis with concomitant pleural adhesion. *Surg Laparosc Endosc* 1996;6:258-61.
97. Kopelman D, Hashmonai M, Ehrenreich M, et al. Upper dorsal thoracoscopic sympathectomy for palmar hyperhidrosis: improved intermediate-term results. *J Vasc Surg* 1996;24:194-9.
98. Lieou FJ, Lee SC, Ho ST, et al. Interpleural bupivacaine for pain relief after transthoracic endoscopic sympathectomy for primary hyperhidrosis. *Acta Anaesthesiol Sin* 1996;34:21-5.
99. Lee KH, Hwang PY. Video endoscopic sympathectomy for palmar hyperhidrosis. *J Neurosurg* 1996;84:484-6.
100. Yilmaz EN, Dur AH, Cuesta MA, et al. Endoscopic versus transaxillary thoracic sympathectomy for primary axillary and palmar hyperhidrosis and/or facial blushing: 5-year-experience. *Eur J Cardiothorac Surg* 1996;10:168-72.
101. Gossot D, Toledo L, Fritsch S, et al. Thoracoscopic sympathectomy for upper limb hyperhidrosis: looking for the right operation. *Ann Thorac Surg* 1997;64:975-8.
102. Chu D, Shi PK, Wu CM. Transthoracic endoscopic sympathectomy for treatment of hyperhidrosis palmaris. *Kaohsiung J Medicalsci* 1997;13:162-8.
103. Tan V, Nam H. Results of thoracoscopic sympathectomy for 96 cases of palmar hyperhidrosis. *Ann Thorac Cardiovasc Surg* 1998;4:244-6.
104. Kopelman D, Hashmonai M, Ehrenreich M, et al. Thoracoscopic sympathectomy for hyperhidrosis: is there a learning curve? *Surg Laparosc Endosc* 1998;8:370-5.

105. Sayeed RA, Nyamekye I, Ghauri AS, et al. Quality of life after transthoracic endoscopic sympathectomy for upper limb hyperhidrosis. *Eur J Surg* 1998;Suppl:39–42.
106. Rex LO, Drott C, Claes G, et al. The Boras experience of endoscopic thoracic sympathectomy for palmar, axillary, facial hyperhidrosis and facial blushing. *Eur J Surg* 1998;Suppl:23–6.
107. Krasna MJ, Demmy TL, McKenna RJ, et al. Thoracoscopic sympathectomy: the U. S. experience. *Eur J Surg* 1998;Suppl:19–21.
108. Lin CC, Mo LR, Lee LS, et al. Thoracoscopic T2-sympathetic block by clipping—a better and reversible operation for treatment of hyperhidrosis palmaris: experience with 326 cases. *Eur J Surg* 1998;Suppl:13–6.
109. Duarte JB, Kux P. Improvements in video-endoscopic sympathectomy for the treatment of palmar, axillary, facial, and palmar-plantar hyperhidrosis. *Eur J Surg* 1998;Suppl:9–11.
110. Heckmann M. Complications in patients with palmar hyperhidrosis treated with transthoracic endoscopic sympathectomy. *Neurosurgery* 1998;42:1403–4.
111. Kao MC. Complications in patients with palmar hyperhidrosis treated with transthoracic endoscopic sympathectomy. *Neurosurgery* 1998;42:951–2.
112. Kopelman D, Hashmonai M, Assalia A, et al. Primary palmar hyperhidrosis presenting with unilateral symptoms: a report of two cases and review of the literature. *Cardiovasc Surg* 1998;6:94–6.
113. Lin TS, Fang HY. Transthoracic endoscopic sympathectomy in the treatment of palmar hyperhidrosis—with emphasis on perioperative management (1,360 case analyses). *Surg Neurol* 1999;52:453–7.
114. Zacherl J, Imhof M, Huber ER, et al. Video assistance reduces complication rate of thoracoscopic sympathectomy for hyperhidrosis. *Ann Thorac Surg* 1999;68:1177–81.
115. Lin TS. Transthoracic endoscopic sympathectomy for palmar and axillary hyperhidrosis in children and adolescents. *Pediatr Surg Int* 1999;15:475–8.
116. Lin TS. Transthoracic endoscopic sympathectomy for palmar hyperhidrosis in children and adolescents: analysis of 350 cases. *J Laparoendosc Adv Surg Techn A* 1999;9:331–4.
117. Tedoriya T, Sakagami S, Ueyama T, et al. Influences of bilateral endoscopic transthoracic sympathectomy on cardiac autonomic nervous activity. *Eur J Cardiothorac Surg* 1999;15:194–8.
118. Fox AD, Hands L, Collin J. The results of thoracoscopic sympathetic trunk transection for palmar hyperhidrosis and sympathetic ganglionectomy for axillary hyperhidrosis. *Eur J Vasc Endovasc Surg* 1999;17:343–6.
119. Chiou TS, Chen SC. Intermediate-term results of endoscopic transaxillary T2 sympathectomy for primary palmar hyperhidrosis. *Br J Surg* 1999;86:45–7.
120. Erak S, Sieunarine K, Goodman M, et al. Endoscopic thoracic sympathectomy for primary palmar hyperhidrosis: intermediate term results. *Aust N Z J Surg* 1999;69:60–4.
121. Reisfeld R, Nguyen R, Pnini A. Endoscopic thoracic sympathectomy for treatment of essential hyperhidrosis syndrome: experience with 650 patients. *Surg Laparosc Endosc Percutan Tech* 2000;10:5–10.
122. Vanaclocha V, Saiz-Sapena N, Panta F. Uniportal endoscopic superior thoracic sympathectomy. *Neurosurgery* 2000;46:924–8.
123. Saiz-Sapena N, Vanaclocha V, Panta F, et al. Operative monitoring of hand and axillary temperature during endoscopic superior thoracic sympathectomy for the treatment of palmar hyperhidrosis. *Eur J Surg* 2000;166:65–9.
124. Lin TS, Huang LC, Wang NP, et al. Endoscopic thoracic sympathetic block by clipping for palmar and axillary hyperhidrosis in children and adolescents. *Pediatr Surg Int* 2001;17:535–7.
125. Lin TS. Video-assisted thoracoscopic “resympathectomy” for palmar hyperhidrosis. analysis of 42 cases. *Ann Thorac Surg* 2001;72:895–8.
126. Gossot D, Kabiri H, Caliendo R, et al. Early complications of thoracic endoscopic sympathectomy: a prospective study of 940 procedures. *Ann Thorac Surg* 2001;71:1116–9.
127. Gossot D, Galetta D, Pascal A, et al. Long-term results of endoscopic thoracic sympathectomy for upper limb hyperhidrosis. *Ann Thorac Surg* 2003;75:1075–9.
128. Atkinson JL, Fealey RD. Sympathectomy instead of sympathectomy for palmar hyperhidrosis: minimizing postoperative compensatory hyperhidrosis. *Mayo Clin Proc* 2003;78:167–72.
129. Lee KS, Chuang CL, Lin CL, et al. Percutaneous CT-guided chemical thoracic sympathectomy for patients with palmar hyperhidrosis after transthoracic endoscopic sympathectomy. *Surg Neurol* 2004;62:501–5.
130. Andrievskikh IA, Fokin AA. Multiyear experience in endoscopic thoracic sympathectomy. *Angiol Sosud Khir* 2004;10:99–104.
131. Yano M, Kiriya M, Fukai I, et al. Endoscopic thoracic sympathectomy for palmar hyperhidrosis: efficacy of T2 and T3 ganglion resection. *Surgery* 2005;138:40–5.
132. Gossot D, Galetta D, Pascal A, et al. Long-term results of endoscopic thoracic sympathectomy for upper limb hyperhidrosis. *Ann Thorac Surg* 2003;75:1075–9.
133. Ganeshmoorthy J, Saravanapavanathan T. A case of hyperhidrosis successfully treated with 20% aluminium chloride hexahydrate in 95% ethyl alcohol. *Singapore Med* 1990;31:85–6.
134. Benohanian A, Dansereau A, Bolduc C, et al. Localized hyperhidrosis treated with aluminum chloride in a salicylic acid gel base. *Int J Dermatol* 1998;37:701–3.
135. Holze E, Alberti N. Long-term efficacy and side effects of tap water iontophoresis of palmo-plantar hyperhidrosis—the usefulness of home therapy. *Dermatologica* 1987;175:126–35.
136. Grice K, Sattar H, Baker H. Treatment of idiopathic hyperhidrosis with iontophoresis of tap water and poldine methosulphate. *Br J Dermatol* 1972;86:72–8.
137. Abell E, Morgan K. The treatment of idiopathic hyperhidrosis by glycopyrronium bromide and tap water iontophoresis. *Br J Dermatol* 1974;91:87–91.
138. Vadoud-Seyedi J. Treatment of plantar hyperhidrosis with botulinum toxin type A. *Int J Dermatol* 2004;43:969–71.

139. Sevim S, Dogu O, Kaleagasi H. Botulinum toxin-A therapy for palmar and plantar hyperhidrosis. *Acta Neurol Belg* 2002;102:167-70.
140. Black MJ, Gunn A. The management of Frey's syndrome with aluminium chloride hexahydrate antiperspirant. *Ann R Coll Surg Engl* 1990;72:49-52.
141. Luh JY, Blackwell TA. Craniofacial hyperhidrosis successfully treated with topical glycopyrrolate. *South Med* 2002;95:756-8.
142. Atkin SL, Brown PM. Treatment of diabetic gustatory sweating with topical glycopyrrolate cream. *Diabet Med* 1996;13:493-4.
143. May JS, McGuirt WF. Frey's syndrome: treatment with topical glycopyrrolate. *Head Neck* 1989;11:85-9.
144. Kyrmizakis DE, Pangalos A, Papadakis CE, et al. The use of botulinum toxin type A in the treatment of Frey and crocodile tears syndromes. *J Oral Maxillofac Surg* 2004;62:840-4.
145. Wang CC, Wang CP. Preliminary experience with botulinum toxin type A intracutaneous injection for Frey's syndrome. *J Chin Med* 2005;68:463-7.
146. Ferraro G, Altieri A, Grella E, et al. Botulinum toxin: 28 patients affected by Frey's syndrome treated with intradermal injections. *Plast Reconstr Surg* 2005;115:344-5.
147. Eckardt A, Kuettner C. Treatment of gustatory sweating (Frey's syndrome) with botulinum toxin A. *Head Neck* 2003;25:624-8.
148. Restivo DA, Lanza S, Patti F, et al. Improvement of diabetic autonomic gustatory sweating by botulinum toxin type A. *Neurology* 2002;59:1971-3.
149. Tugnoli V, Marchese RR, Eleopra R, et al. The role of gustatory flushing in Frey's syndrome and its treatment with botulinum toxin type A. *Clin Auton Res* 2002;12:174-8.
150. Guntinas-Lichius O. Increased botulinum toxin type A dosage is more effective in patients with Frey's syndrome. *Laryngoscope* 2002;112:746-9.
151. Beerens AJ, Snow GB. Botulinum toxin A in the treatment of patients with Frey syndrome. *Br J Surg* 2002;89:116-9.
152. Laccourreye O, Akl E, Gutierrez-Fonseca R, et al. Recurrent gustatory sweating (Frey syndrome) after intracutaneous injection of botulinum toxin type A: incidence, management, and outcome. *Arch Otolaryngol Head Neck Surg* 1999;125:283-6.
153. Kyrmizakis DE, Pangalos A, Papadakis CE, et al. The use of botulinum toxin type A in the treatment of Frey and crocodile tears syndromes. *J Oral Maxillofac Surg* 2004;62:840-4.
154. Eckardt A, Kuettner C. Treatment of gustatory sweating (Frey's syndrome) with botulinum toxin A. *Head Neck* 2003;25:624-8.
155. Kinkelin I, Hund M, Naumann M, et al. Effective treatment of frontal hyperhidrosis with botulinum toxin A. *Br J Dermatol* 2000;143:824-7.
156. Drott C. Results of endoscopic thoracic sympathectomy (ETS) on hyperhidrosis, facial blushing, angina pectoris, vascular disorders and pain syndromes of the hand and arm. *Clin Auton Res* 2003;13(Suppl 1):I26-I30.
157. Lin TS, Chou MC. Needlescopic thoracic sympathetic block by clipping for craniofacial hyperhidrosis. an analysis of 28 cases. *Surg Endosc* 2002;16:1055-8.
158. Chen HJ, Lu K, Liang CL. Transthoracic endoscopic T-2,3 sympathectomy for facial hyperhidrosis. *Auton Neurosci* 2001;93:91-4.
159. Kao MC. Thoracoscopic sympathectomy for craniofacial hyperhidrosis. *Eur J Cardiothorac Surg* 2001;19:951-2.

Address correspondence and reprint requests to: Nowell Solish, MD, FRCPC, Dermatologist, New Women's College Hospital, 76 Grenville Street, Room 841, Toronto, Ontario M5S 1B2, Canada, or e-mail: n.solish@utoronto.ca